Case 26: Questions & Answers:

www.stemiecg.com

1. STEMI? Yes.

2. Territory? Anterior wall.

3. What is the Culprit Vessel? Proximal left anterior descending (LAD) artery.

ECG findings:

- Anterior and lateral precordial T-wave peaking on the precordial leads (V2-V5) with an up slopping oblique ST segment elevation merging with the T wave.

Teaching Points:

- In the early stages of AMI the ECG may be normal or with only subtle changes (mentioned below).
- Less than 50% of patients with AMI have clear diagnostic changes on their first ECG trace.
- In most cases, however, serial ECG's (10-15 minute intervals) show evolving changes that tend to follow well-recognized patterns.
- **Hyperacute phase of an AMI** (initial minutes) may include the following:
    - Subtle enlargement of the T-wave, disproportionate to the QRS
    - Peaking T-waves with a bulky and wide appearance. Localized to the region of infarction. QT segment may be prolonged.
    - The ST segment elevation may be subtle, not diagnostic, with a straightening of the normal upward concavity between the ST segment and T-wave. This gives an appearance of an oblique merging of the T-wave & ST segment, going from an upward concavity to an eventual convexity, which characterizes a STEMI.
    - For this reason it is suggested to read the ST segment change (compared to the PQ segment reference) 40 msec beyond the J-point to increase the sensitivity of the interpretation, mostly if related to a patient with clinical picture suggestive of AMI.
    - Keep in mind that other conditions may present with prominent T-waves, such as LVH, early repolarization abnormalities and hyperkalemia. The first two, usually are chronic changes (non-dynamic) and with asymmetric T-waves. With hyperkalemia the Tw is thin based and not localized.
    - Helpful diagnostic tools or strategies: look for reciprocal ST segment depressions, compare with past ECGs (as in this case), perform serial ECGs, perform a limited bedside echocardiogram (to assess wall motion abnormality corresponding to the ECG territory with the ST & Tw abnormalities), cardiac markers, and coronary angiography (mostly if clinical picture is very suggestive of AMI).

Baseline ECG:

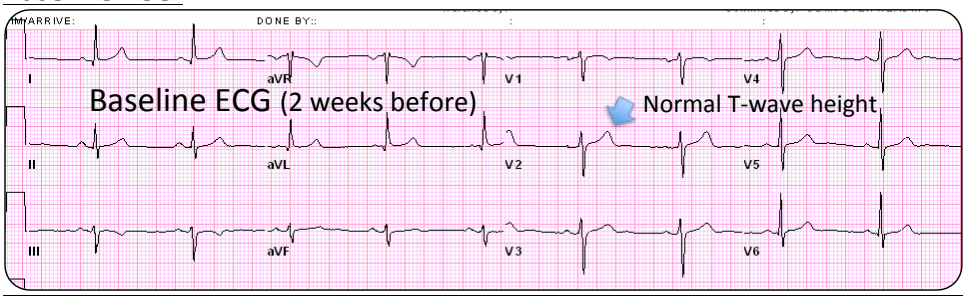

Arrival ECG:

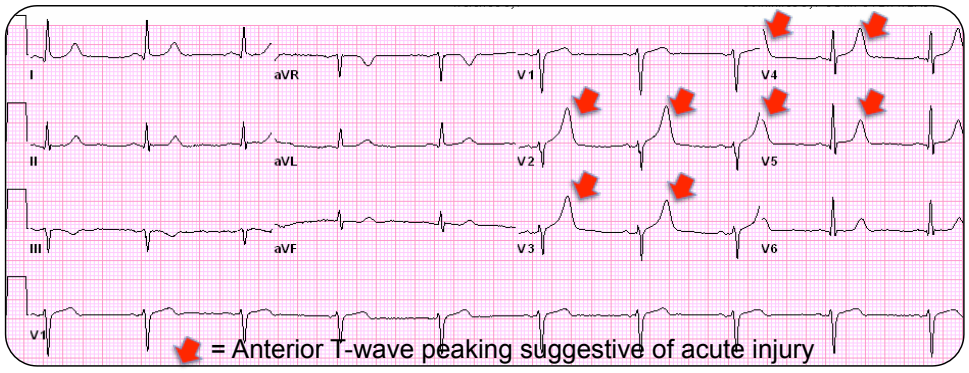

F/U ECG (20 minutes after arrival):

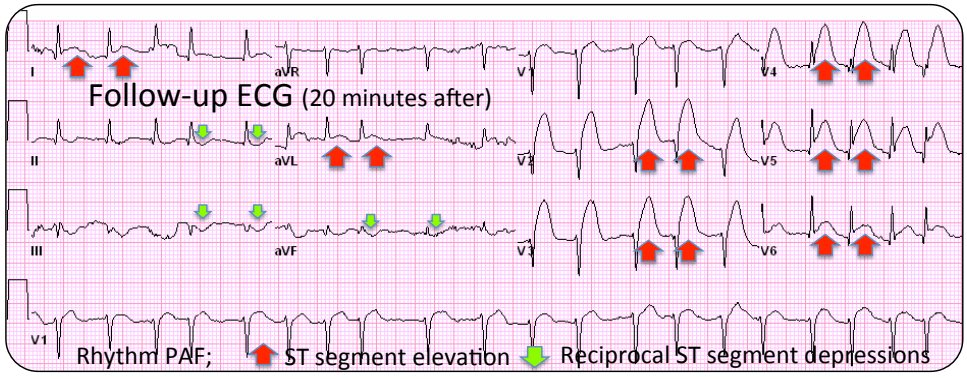

Coronary angiography:

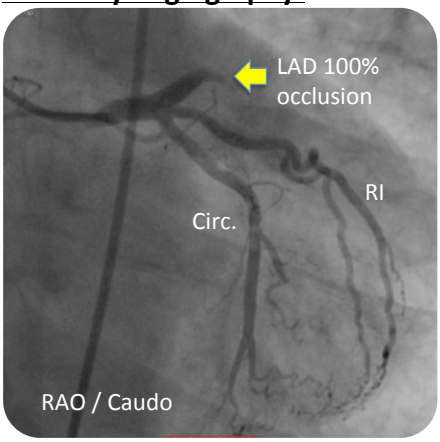

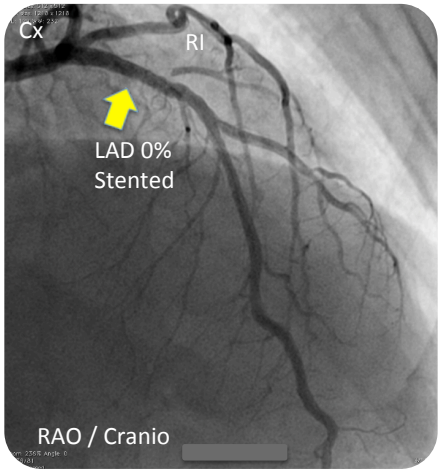

By: Jose Escabí, MD